

## On the Mylohyoid Canal in the Human Mandible

By

**Shuji YAMANO**

Faculty of Veterinary Medicine, Hokkaido University, Sapporo

and

**Bin YAMAGUCHI**

Department of Anthropology, National Science Museum, Tokyo

### Introduction

The groove for the mylohyoid nerve and blood vessels on the medial surface of the ramus of the human mandible is occasionally covered by one or two bony bridges at various positions of its course from the mandibular foramen to the antero-inferior extremity under the mylohyoid line. Such variant trait of the mylohyoid groove has been called the mylohyoid canal (*Canalis mylohyoideus*) by anatomists. Little attention had been paid to this structure by anthropologists until LAUGHLIN & JØRGENSEN (1956), who called this trait the mylohyoid arch, recorded its incidences in four cranial series of the Greenland Eskimo as one of the discrete craniological traits to which they applied inter-populational distance analysis. Since then, however, recording the incidence of the mylohyoid bridging has become routine in standard craniological survey of recent as well as earlier human skeletal populations.

The present authors encountered a considerably high incidence and interesting anatomical features of this trait in prehistoric human skeletal materials from Hokkaido in northern Japan. The purposes of this article are to discuss the causative factor of the mylohyoid bridging from anatomical point of view based on the materials at hand, and also to review and compare the incidence data of various populations in the Circum-Pacific area.

### Anatomy and Nature of the Mylohyoid Canal

Two different forms can be distinguished in the bony bridging over the mylohyoid groove: one is the bridging at the proximal extremity of the groove involving the mandibular foramen, and the other is that in the distal course of the groove. The former is designated here as the lingular type, or L type for short, since the bridge is formed by extraordinary backward development of the lingula that reaches the posterior margin of the mandibular foramen. The latter form is named as the bridge type, or B type (Fig. 1). On rare occasions, bridges of both types occur simultaneously,



Fig. 1. Two types of the mylohyoid canal: the bridge type (left) and the lingular type (right).

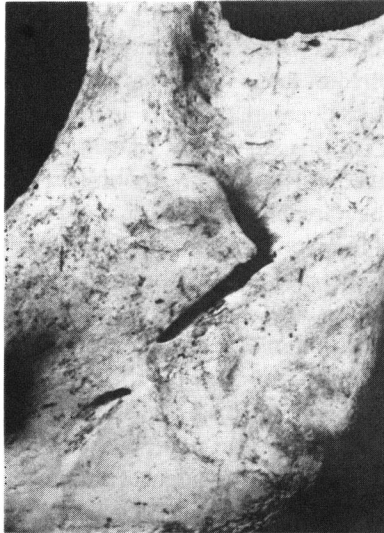

Fig. 2. Bridge type mylohyoid canal in an Ainu mandible (Hamatōei 6). A bony ridge for muscle attachment extends from the pterygoid tuberosity antero-superiorly and traverses the mylohyoid groove over the bony plate of the mylohyoid canal.

as shown in Figs. 3 and 4.

An interesting configuration, with regard to the question of the etiological factors of the B type mylohyoid canal, was found in an Ainu mandible from Hokkaido. As shown in Fig. 2, the mylohyoid groove is bridged by a narrow bony plate in the middle of its course, and one of the several bony ridges for the medial pterygoid attachment extends from the pterygoid tuberosity upward to traverse the groove just over that

bony plate. Such a configuration seems to imply that the B type mylohyoid canal is brought about by partial ossification of the connective tissue covering the mylohyoid nerve and vessels as a reaction to the strong tension exerted by extraordinarily developed anterior bundles of the medial pterygoid muscle. The fact that the insertion of the medial pterygoid muscle is not always confined to the area behind the mylohyoid groove but can occasionally extend antero-superiorly across the groove has been confirmed in a few cadavral mandibles at the dissection room of Sapporo Medical College.

On the other hand, the typical lingular type mylohyoid canal, as shown in Fig. 1, gives an unusual appearance to the mandibular foramen. It thus appears as if it were another variant trait entirely independent from the B type mylohyoid canal. However, if several transitive forms representing various developmental stages of the mylohyoid canal are arranged in a morphological order, as shown in Fig. 3, the sequence makes it clear that the L type bridging is not independent of other mylohyoid bridging but is only a part of the same morphological trait, namely, the partial ossification of the connective tissue covering the mylohyoid nerve and vessels. In the case of double mylohyoid canal comprising both L and B type bridgings shown in Fig. 4, both of the bony bridges provide the medial pterygoid with attachment area, as clearly demonstrated by the bony ridges running over those bridges. These morphological details, as exemplified by the cases shown in Figs. 2-4, provide sufficient evidence for a close

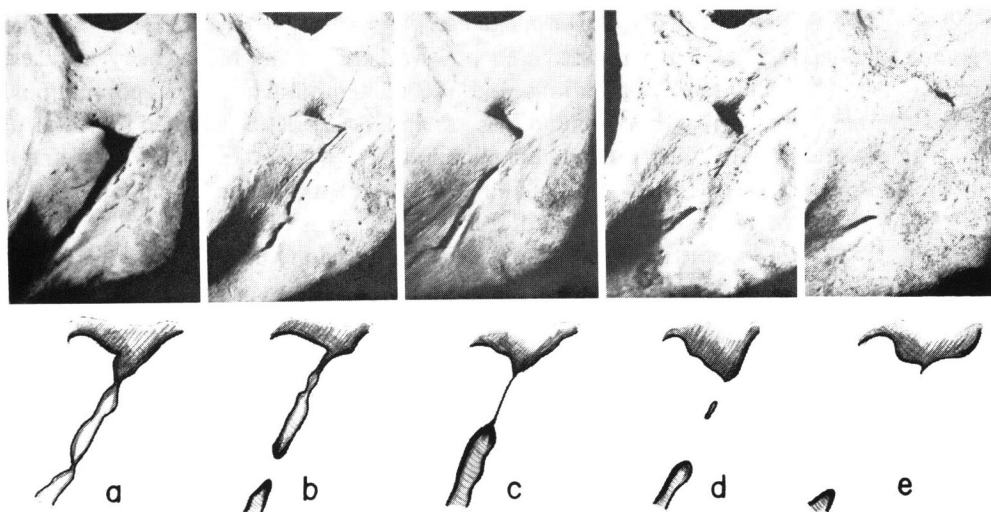


Fig. 3. Five transitive forms representing various developmental stages of the mylohyoid bridging. a: typical lingula and deep mylohyoid groove (Hamatōei Ainu 26); b: posteriorly developed lingula and a narrow bridge (Onkoromanai 5); c: the lingula just in contact with bony process from posterior margin of mandibular foramen (Ōmisaki 5); d: combination of lingular and bridge type canals (Toyota Ainu 26); e: fused lingular and bridge type canals (Usakumai 4).

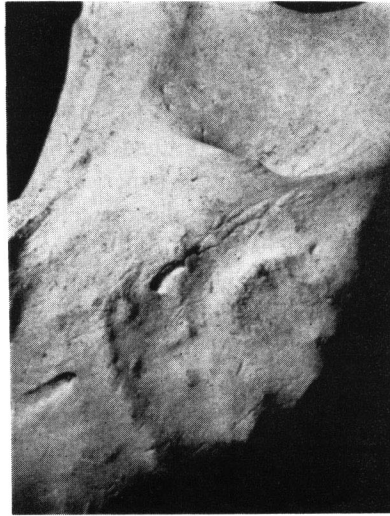

Fig. 4. Typical lingular bridging accompanied by a long bridge type canal in a prehistoric mandible (Bōzuyama VI-2). Four bony ridges for the medial pterygoid muscle traverse the groove over these bridges.

relationship between the mylohyoid canal of both types and the insertion of the medial pterygoid muscle.

It may then be expected that the incidence of this trait be relatively high in the populations characterized by frequent and powerful use of the masticatory muscles, such as the early hominid populations and the contemporary pongid populations, because pongid and early hominid mandibles are apparently better adapted to powerful masticatory movements than recent human mandibles. According to WEIDENREICH (1936), however, the structures of the mandibular foramen and the mylohyoid groove of the *Sinanthropus* mandibles do not differ from those of modern man.

STRAUS (1962) observed seven cases of the bridged mylohyoid groove in 161 gorilla half-mandibles (4.3%), but found no such instances in his chimpanzee and orang materials. VOGEL (1963) also observed that there were no instances of the mylohyoid bridging in the Ponginae and the Hylobatidae with the exception of the gorilla. VOGEL's gorilla material consisted of 86 half-mandibles of the lowland gorilla from west Africa and 82 of the mountain gorilla from central Africa. Incidence of the mylohyoid canal was 2.3 percent in the former and 26.8 percent in the latter. Similar intrageneric (or intraspecific) difference was also observed in non-adult materials.

In view of these facts, the mylohyoid canal seems to be one of minor variants of micro-evolutional significance rather than a character of phylogenetic significance.

#### **Incidences of the Mylohyoid Canal in Circum-Pacific Populations**

Incidences of the mylohyoid canal in two series of prehistoric human remains from Hokkaido, kept at Sapporo Medical College, and in another from eastern Honshu,

Table 1. Incidences of the lingular type mylohyoid canal and of the inclusive mylohyoid bridging in some Circum-Pacific populations.

Mandibular Series	Examined by	Sex	No. of sides	Lingular (%)	Inclusive (%)
Jomon and epi-Jomon, Hokkaido	Present authors	M & F	46	5 (10.9)	11 (23.9)
Okhotsk culture, Hokkaido	Present authors	M & F	42	2 (4.8)	5 (11.9)
Jomon, eastern Honshu	Present authors	M & F	96	3 (3.1)	12 (12.5)
Ainu, Hokkaido	DODO and present authors	M	167	3 (1.8)	23 (13.8)
		F	108	1 (0.9)	6 (5.6)
		M & F	275	4 (1.5)	29 (10.5)
Japanese, eastern Honshu	DODO	M	259	8 (3.1)	12 (4.6)
		F	96	1 (1.0)	3 (3.1)
		M & F	355	9 (2.5)	15 (4.2)
Australian Aboriginal	YAMAGUCHI	M	348	4 (1.1)	22 (6.3)
		F	257	6 (2.3)	15 (5.8)
		M & F	605	10 (1.7)	37 (6.1)
Polynesian	PIETRUSEWSKY	M	243	13 (5.3)	21 (8.6)
		F	243	11 (4.5)	16 (6.6)
		M & F	486	24 (4.9)	37 (7.6)
Iroquoian, Ontario	YAMAGUCHI	M & F	275	14 (5.1)	60 (21.8)

in the collection at the National Science Museum, Tokyo, have been investigated and compared with those of various recent populations in the Circum-Pacific area (Table 1).

The materials of Jomon and epi-Jomon periods in Hokkaido are composed of 4 mandibles from Takasago and Irie shell mounds in Abuta, 1 from Midorichō site in Abashiri, 5 from Onkoromanai site in Wakkanai, 11 from Midorigaoka site in Kushiro, 3 from Bōzuyama site in Ebetsu, 1 from Rebunge shell mound in Toyoura, and 3 from Usakumai site in Chitose.

Those of the Okhotsk culture period in Hokkaido consist of 24 mandibles from Ōmisaki site in Wakkanai.

The materials of Jomon period in Honshu are all from shell mounds in eastern half of Honshu. Sizes of the samples and the names of the sites and prefectures are as follows: 19 mandibles from Ebishima in Iwate, 1 from Satohama in Miyagi, 6 from Sanganji in Fukushima, 15 from Ubayama and Horinouchi in Chiba, 1 from Shosenzuka in Kanagawa and 15 from Ikawazu in Aichi.

Incidence data for the Hokkaido Ainu of the KOGANEI Collection kept in the University Museum of the University of Tokyo and for the recent Japanese series from Kantō and Tōhoku districts in the collections at the Departments of Anatomy in Sapporo Medical College and in Tōhoku University School of Medicine were afforded to us by courtesy of Y. DODO (see DODO, 1974 for material descriptions). DODO's Ainu data for the KOGANEI series were combined with the data for another Hokkaido Ainu series in the Sapporo Medical College skeletal collection recorded

by the present authors.

The provenances of the Australian Aboriginal materials examined by the senior author were recorded elsewhere (YAMAGUCHI, 1967).

Polynesian data have been quoted from the doctoral dissertation of M. PIETRUSEWSKY (1969), who used the same criteria of trait recording. The original data given separately for Society, Tuamotu, Marquesas, Hawaii, Easter, New Zealand, Chatham and Tonga-Samoa were combined by the present authors.

Iroquoian data were obtained by the senior author from an early historic ossuary material excavated at Carton site in Ontario and kept at the University of Toronto.

Data reported by other authors who did not record the L and B types separately have also been quoted and added to the list in Table 2, where only the incidences of inclusive bridging are given for sex combined series.

It can be seen from Table 1 that the mylohyoid canal generally occurs more frequently in male mandibles than in female, but the sex differences of the incidence are slight and hardly significant statistically. The incidences of the lingular type canal are less than half of the total incidences with the exceptions of the male and female Polynesian and the male Japanese series, where more than half of the mylohyoid canal are of the lingular type.

As for population incidence of the total mylohyoid canal, Table 2 shows that considerably high incidences in the North American Indians and the Aleuts are in marked contrast to low incidences in the Formosan Aborigines, recent Japanese, Australian Aborigines, Eskimo, and Polynesians. Intermediate are the Hokkaido Ainu,

Table 2. Incidences of the mylohyoid canal inclusive of both lingular and bridge types in Circum-Pacific populations.

Populations	Authors	No. of sides	Incidences
Polynesians	PIETRUSEWSKY, 1969	486	37 ( 7.6)
Australian Aborigines	YAMAGUCHI, 1967	605	37 ( 6.1)
Formosan Aborigines	IMAI, 1936	68	2 ( 2.9)
Japanese	DODO, 1974	355	15 ( 4.2)
Japanese	HASEBE, 1916, etc.*	986	28 ( 2.8)
Jomon and eastern Honshu	—	96	12 (12.5)
Ainu, Hokkaido	—	275	29 (10.5)
Jomon and epi-Jomon, Hokkaido	—	46	11 (23.9)
Okhotsk culture, Hokkaido	—	42	5 (11.9)
Eskimo, Greenland	LAUGHLIN & JØRGENSEN, 1956	288	23 ( 8.0)
Eskimo, Alaska	OSSENBERG, 1969	246	12 ( 4.9)
Aleuts	OSSENBERG, 1969	233	60 (25.7)
Haida	CYBULSKI, 1975	153	26 (17.0)
Kwakiutl, Nootka and Coast Salish	CYBULSKI, 1975	251	47 (18.7)
Iroquois, Ontario	—	275	60 (21.8)
Prehistoric mounds, northern Plains	OSSENBERG, 1969	430	128 (29.8)
Pueblo	CORRUCCINI, 1972	517	68 (13.2)

\* SUZUKI, 1920; MISAKI & NISHIDA, 1956; FURUTA, 1962.

prehistoric Okhotsk series from Hokkaido, and prehistoric Jomon series from Honshu. The Jomon and epi-Jomon series from Hokkaido is close to the North American Indian series with its high incidence.

In addition to the macro-geographic contrast between high incidences in America and low incidences in East Asia and Oceania in general, there exists local geographic variation of incidence as demonstrated by the data of the Aleut-Eskimo populations in arctic North America.

With regard to temporal trend in the incidence of the mylohyoid canal, it is interesting to find parallel decreasing trends from prehistoric to modern series in the Ainu in Hokkaido and the Japanese in Honshu. A similar temporal trend of this trait was also reported by ANDERSON (1968) for the materials from a prehistoric site in Ontario.

Such a temporal trend in the incidence of the mylohyoid bridging recognized in both Asia and America may seem to be explainable as a result of decrease in the stress exerted to the mandible by the masticatory muscles, in view of the close relationship between the canal formation and the medial pterygoid muscle pointed out in the preceding chapter. However, the fact that the Eskimo and the Australian Aborigines who are well-known for excessive use of the masticatory organs are among the populations with rather low incidence of the mylohyoid canal remains to be explained. A more complicated model taking plural factors, such as position and course of the mylohyoid groove, size and form of the angle of the mandible, and hereditary hyperostotic predisposition, into consideration is needed to understand the pattern of incidence variations of the mylohyoid canal in the human mandible.

### Summary

Two types of the bony bridging of the mylohyoid groove in the human mandible, namely, the lingular (L) and the bridge (B) types, were examined anatomically for the materials from northern Japan. It was concluded that these two forms were closely related expressions of one and the same trait, that is the ossification of the connective tissue covering the mylohyoid nerve and vessels as a reaction to the stress exerted by the medial pterygoid muscle.

The incidences of the mylohyoid canal among the prehistoric series from Hokkaido and eastern Honshu were compared with those of various populations in the Circum-Pacific area. In addition to a large scale geographical contrast between low incidence in East Asia and Oceania and high incidence in North America, local geographical as well as temporal variations in incidence were demonstrated to exist. It was discussed that not only the masticatory stress but other factors were also needed to explain the pattern of the incidence variations of this trait.

### Acknowledgments

We acknowledge that the main part of this work was done, while we were in

the Department of Anatomy in Sapporo Medical College, on the material under the custody of Prof. K. MITSUHASHI. We are also very grateful to Drs. Y. DODO, N. OSSENBERG and M. PIETRUSEWSKY who allowed us to quote their unpublished data on the incidence of the mylohyoid bridging.

### References

- ANDERSON, J. E., 1968. The Serpent Mounds site physical anthropology. *Art and Archaeol. Occas. Paper*, (11): i-vi+1-97 pp. Toronto, Royal Ontario Museum.
- CORRUCCINI, R. S., 1972. The biological relationships of some prehistoric and historic Pueblo populations. *Am. J. Phys. Anthrop.*, **31**: 373-388.
- CYBULSKI, J. S., 1975. Skeletal variability in British Columbia coastal populations: A descriptive and comparative assessment of cranial morphology. *Archaeol. Survey of Canada Mercury Series Paper*, (30): i-xvi+1-313 pp. Ottawa, National Museum of Man.
- DODO, Y., 1974. Non-metrical cranial traits in the Hokkaido Ainu and the northern Japanese of recent times. *J. Anthrop. Soc. Nippon*, **82**: 31-51.
- FURUTA, Y., 1962. Über die Bildung der Incisura foraminis mandibulae sowie des Canalis mylohyoideus. *Yokohama Med. Bull.*, **13**: 371-381.
- HASEBE, K., 1916. Canalis mylohyoideus. *Tohoku Igaku Zasshi*, **1**: 224. (In Japanese.)
- IMAI, M., 1936. Anatomische und anthropologische Untersuchungen des Unterkiefers von Formosa-Wilden. *Dainippon Shikagakkai Kaishi (J. Japan. Odont. Soc.)*, **79**: 255-291. (In Japanese.)
- LAUGHLIN, W. S., & J. B. JØRGENSEN, 1956. Isolate variation in Greenlandic Eskimo crania. *Acta Genet. Stat. Med.*, **6**: 3-12.
- MISAKI, K., & O. NISHIDA, 1956. Anatomical study on the mylohyoid groove in Japanese mandibles. *Tokyo-Shika-Daigaku Kaibo. Gyoseki.*, (1). (In Japanese.)
- OSSENBERG, N. S., 1969. Discontinuous morphological variation in the human cranium. Doctoral dissertation, University of Toronto.
- PIETRUSEWSKY, M., 1969. The physical anthropology of early Tongan populations: A study of bones and teeth and an assessment of their biological affinities based on cranial comparisons with eight other Pacific populations. Doctoral dissertation, University of Toronto.
- STRAUS, W. L. JR., 1962. The mylohyoid groove in primates. *Bibl. Primat.*, **1**: 197-216. (Cited by Vogel, 1963.)
- SUZUKI, B., 1920. Jintai Keito Kaibogaku (Systematic Human Anatomy). 2nd ed., vol. 1, Tokyo. (In Japanese.)
- VOGEL, C., 1963. Sulcus mylohyoideus, Foramen mandibulae und Sulcus retrotoralis bei Ponginen und Hylobatiden. *Folia Primat.*, **1**: 103-121.
- WEIDENREICH, F., 1936. The mandibles of *Sinanthropus pekinensis*: A comparative study. *Palaeont. Sin., Ser. D*, **7** (3): 1-132, pls. 1-15.
- YAMAGUCHI, B., 1967. A comparative osteological study of the Ainu and the Australian Aborigines. *Austral. Inst. Abor. Stud. Occas. Paper*, (10): 1-73.