

# The Nerve Bundle via the Median Nerve Innervating the Ulnar Intrinsic Muscles of the Hand in a Gorilla Equivalent to the Deep Branch of the Ulnar Nerve in the Human

Hidehiko Saito<sup>1,\*</sup>, Tadasu K. Yamada<sup>2</sup> and Yuko Tajima<sup>2</sup>

<sup>1</sup>Retired hand surgeon, Seirei Hamamatsu Hospital, Hamamatsu, Japan

<sup>2</sup>Department of Zoology, National Museum of Nature and Science,

4–1–1 Amakubo, Tsukuba, Ibaraki 305–0005, Japan

\*E-mail: h-saito@grape.plala.or.jp

(Received 20 May 2023; accepted 20 September 2023)

**Abstract** The ulnar antebrachial branch of the median nerve (UABM) was found in the right forelimb of a female western gorilla (*Gorilla Gorilla*) estimated 40 years old. It branched off the median nerve at the anterior aspect of the elbow and ran ulno-distally in the forearm toward the wrist. In the distal forearm, it bifurcates into the ulnar and radial bundles; the ulnar bundle is a sensory branch and the radial one is a motor branch. The radial one goes around the hook of the hamate deep into the palm and then radially as the deep branch of the ulnar nerve does in the human hand. The radial bundle innervates ulnar intrinsic muscles (all intrinsic muscles except for thenar muscles and radial two lumbricals). The proximal-ward intraneural dissection revealed that most nerve fibers of this UABM come from the medial cord and some from the lateral cord, and that further proximally one half of fasciculi coming from the medial cord originates from the medial division (Eisler) of the middle trunk·C7 root and the other half from the lower trunk·C8 root. We are not sure that this branch of the median nerve innervating the ulnar intrinsic muscles of the hand is the common structure of the nervous system in the forelimb of the gorilla.

**Key words:** anatomy, ulnar antebrachial branch, median nerve, gorilla, ulnar intrinsic muscles, all median hand, Martin-Gruber anastomosis.

## Introduction

The ulnar antebrachial branch of the median nerve (UABM) was found in an ordinary anatomical dissection of the right forelimb of a gorilla (Fig. 1) (Saito, 2020; Saito *et al.*, 2021). It innervates all intrinsic muscles except for thenar muscles and radial two lumbricals of the hand. We call those intrinsic muscles here ulnar intrinsic muscles (Fig. 2). All ulnar muscles are innervated by the deep branch of the ulnar nerve in the common type of the human anatomy. The main purpose of this anatomical study is to find out from which nerve-root this UABM comes out

and which trunk and cord it comes through in order to consider its embryonic development. The other purpose is to compare the connection between this branch and the ulnar nerve with Martin-Gruber anastomosis that is the one between the median and the ulnar nerves occasionally seen in the human forearm.

## Materials and Methods

The specimen used for this study was offered from the National Museum of Nature and Science, Tsukuba Japan, and the study itself was carried out under the direction of co-authors there.

The right forelimb of a female western gorilla

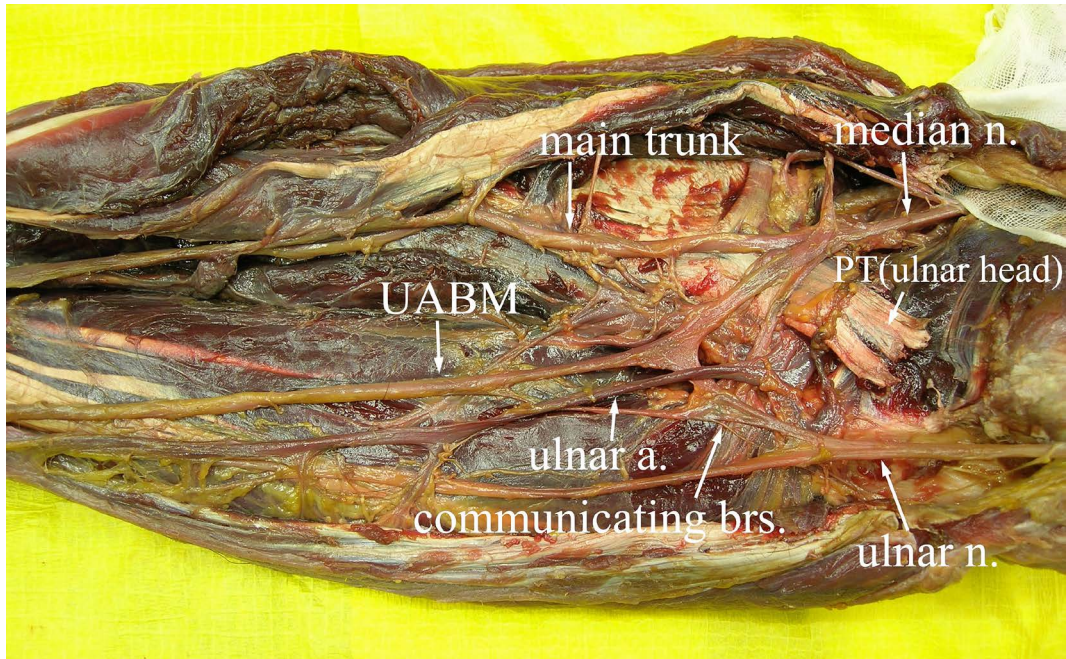


Fig. 1. Ulnar antebrachial branch of the median nerve (UABM). It branched off the median nerve at the anterior aspect of the elbow and ran ulno-distally in the forearm toward the wrist. The ulnar artery is seen to come out from under the ulnar head of the pronator teres and to run distally along but about one cm apart from UABM.

(*Gorilla Gorilla*) estimated 40years old that died at Ueno Zoo in Tokyo was used for this anatomical dissection. The forelimb had been amputated at the level of the lateral margin of the cervical spines without identifying each cervical root.

Anatomical dissection was carried out under 3.5 times magnification of surgical loupes, and also 4.0–16 times magnification of an operating microscope especially for intraneural funicular dissection. After peeling off the skin and subcutaneous tissue, the anatomical dissection was carried out to identify the individual muscles and the nerves in the routine manner. The scapula and clavicle were first dissected off the muscles and then removed out as one piece by disarticulating the shoulder joint. The bones and joints below the shoulder joint were dissected off the soft tissues through the extended ulnar approach and extracted out en-masse while the muscles being attached to the innervating nerves in order to make the muscle-nerve specimen of the entire forelimb from the level of the nerve-root to the

fingertip.

The specimen was kept in formalin solution for a few weeks and then spread in water-formalin solution in a large tray. Individual muscles and nerves are identified. Arteries and veins running along nerve trunks and branches were separated off the latter and discarded to clarify individual nerves and innervating muscles.

The intraneural dissection of the individual nerves was carried out by removing the external epineurium in the solution under the magnification using an operating microscope. Each fasciculus (nerve fiber bundle covered with the perineurium) was isolated by removing the interfascicular epineurium, and then followed as proximally as possible from the neuromuscular junction (the end point of each motor branch in the muscle visible with the naked eyes) to the nerve-root.

The UABM was first dissected proximally and separated from the anterior interosseous nerve and the main trunk of the median nerve. It was

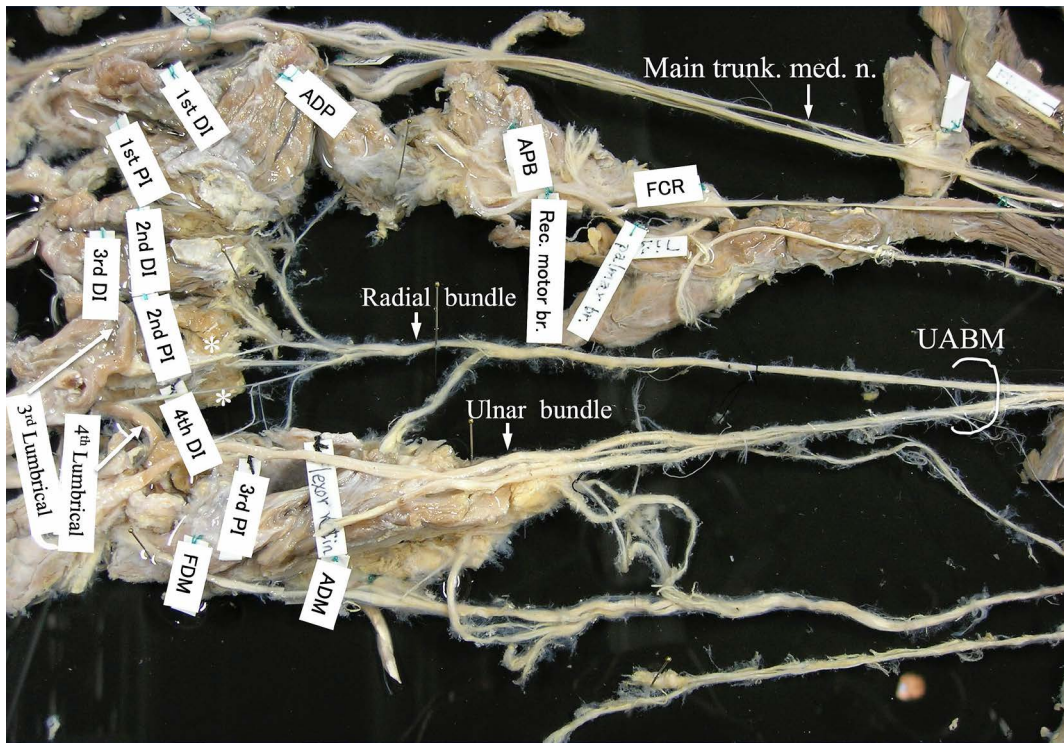


Fig. 2. Innervation of all ulnar intrinsic muscles by the radial bundle of UABM. The radial bundle (motor branch) first gives off branches to the hypothenar muscles and to the lumbrical muscles of the little and ring fingers (marked with asterisks), and then to interossei (4th DI, 3rd PI and 3rd DI, 2nd PI). It goes further radially to give branches to both heads of ADP.

then dissected proximally toward the level of the roots by using the intraneural dissection technique in order to clarify from which nerve-roots the nerve fibers of this branch come out and which trunk and cord they come through.

The findings were then compared first with those described in the Raven's book 'Anatomy of the gorilla' (Gregory, 1950) and then with descriptions in the established textbooks of the human anatomy (Lampe and Netter, 1951; Chusid and McDonald, 1964; Boileau Grant and Basmajian, 1965; Kaplan, 1965; Hollinshead, 1969; Lampe, 1974; Anderson, 1983; Ueba, 1985; Tountas and Bergman, 1993) and also the pertinent papers including the anatomy of the brachial plexus in other species of anthropoids (Kusakabe *et al.*, 1965; Nishimura *et al.*, 1965; Kusakabe, 1976) and finally analyzed from the standpoint of a hand surgeon. For simplicity, the name of each

finger was substituted by that of the corresponding finger of the human hand to facilitate understanding the anatomical differences between the gorilla's forelimb and the human upper extremity.

## Results

### 1) Brachial plexus

The problem of this specimen is that the forelimb had been amputated without identifying each cervical root in advance of this anatomical study. So, the number of each root was judged from the whole structure of the plexus; the upper trunk composed of the fifth cervical (C5) and the sixth cervical (C6) roots, the middle trunk composed of the seventh cervical (C7) root and the lower trunk composed of the eighth cervical (C8) root (Fig. 3A). A thin nerve bundle was judged to be the fourth cervical (C4) root sitting just cra-

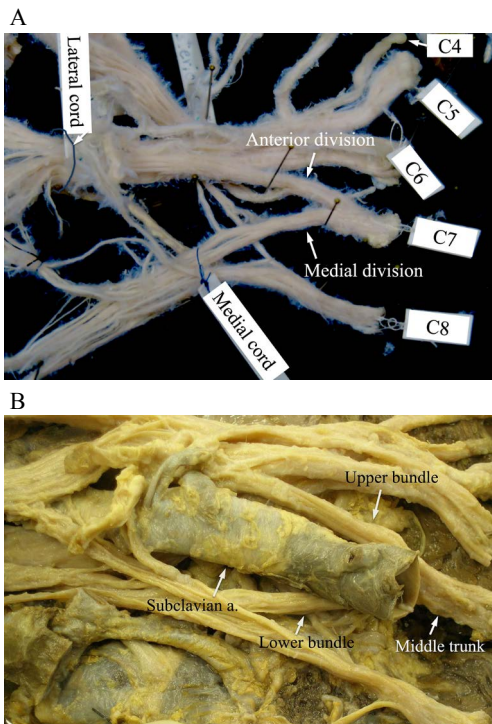


Fig. 3. Brachial plexus. A. The brachial plexus is composed of the upper trunk·C4, C5 and C6 roots, the middle trunk·C7 root and the lower trunk·C8 root. B. The subclavian artery was found to split the middle trunk into two bundles: upper and lower. The upper bundle consists of the anterior and posterior divisions, and the lower bundle is the medial division (Eisler) going to the medial cord.

nial to the upper trunk. There was not any contribution from the first or the second thoracic (Th1/2) root to the lower trunk. The brachial plexus of this specimen was judged to be composed of mainly C5 to C8 roots and thin nerve root of C4. It is considered to be such a type as the prefixed brachial plexus in the human.

In this specimen with the large vessels and surrounding soft tissue attached to the brachial plexus, the subclavian artery was found to split the middle trunk·C7 root into two bundles: upper and lower (Fig. 3B). The upper bundle consists of the anterior and posterior divisions; the anterior goes to the lateral cord and the posterior does to the posterior cord. The lower bundle is the medial

division (Eisler) going to the medial cord.

## 2) Ulnar antebrachial branch of the median nerve (UABM)

### a) Its route and branches

The median nerve trifurcates at the level of the distal border of the pronator teres. The most radial branch is the main trunk and the most ulnar one is the UABM branch (Saito 2020; Saito *et al.*, 2021). The last one, the anterior interosseous nerve, comes out from the radio-posterior portion of the latter.

The UABM runs ulno-distally toward the ulnar side of the wrist and comes close to, but does not unite with the ulnar nerve. It bifurcates there, and its ulnar bundle goes distally along the radial border of the hypothenar muscles. Its radial one goes around the hook of the hamate deep into the palm and then radial-ward as the deep branch of the ulnar nerve does in the human hand. The ulnar bundle further bifurcates, one being the ulnar digital nerve of the little finger and the other the 3rd common digital nerve going to the 4th interdigital space. The radial bundle first gives off a branch to the hypothenar muscles and then branches to the lumbrical muscles of the little and ring fingers, and then to both dorsal and palmar interossei; 4th DI (dorsal interosseous), 3rd PI (palmar interosseous) and 3rd DI, 2nd PI, in the 4th and 3rd intermetacarpal spaces (Fig. 2). It goes further radially to give branches to both the transverse and the oblique heads of the adductor pollicis (ADP). Its terminal branch goes through the interval between those two heads of ADP and comes out to the post-adductor space to innervate both dorsal and palmar interossei (2nd DI, 1st PI) in the 2nd intermetacarpal space and finally both heads of the 1st DI in the 1st intermetacarpal space. So, the radial bundle of the UABM innervates all ulnar intrinsic muscles.

It is essential to discriminate between those nervous branches and the vascular ones. The route and branching pattern of metacarpal arteries from the deep palmar arterial arch composed of the deep branch of the radial artery and that of the ulnar artery (Lampe, 1951; Hollinshead,

1969) resemble those of this radial bundle of UABM. It was confirmed that those branches innervating intrinsic muscles were continuous with the radial bundle of UABM.

### b) Components

It was found that most nerve fibers of the UABM come from the medial cord and some from the lateral cord (Fig. 4A). Intraneural dissection of the medial cord revealed that one half of fasciculi going to UABM come from the medial division of the middle trunk·C7 root (Eisler) and the other half from the lower trunk·C8 root (Fig. 4B). Several fasciculi of C8 root going to the UABM pass anterior or posterior to the ulnar nerve; two thick fasciculi anterior, and two thick and one thin fasciculi posterior (Fig. 5). Three fasciculi from the lateral cord join the UABM (Fig. 5).

## 3) The ulnar nerve

### a) Component

The ulnar nerve emerging from the medial cord is composed of fasciculi from C7 and C8 roots; five of 12 fasciculi of the medial division of the middle trunk·C7 root and three thick and a few thin fasciculi from the lower trunk·C8 root (Fig. 4A). There was not found such a nerve bundle coming from the lateral cord to form the ulnar nerve as seen on the Plate 22 of Raven's book (Gregory, 1950). The fasciculi going to the ulnar nerve through the medial division of the middle trunk (Eisler) does contain motor fibers going to the forearm muscles (FCU, FDPV) but does not those to intrinsic muscles of the hand.

### b) Motor branches to FCU muscle

The ulnar nerve sends three motor branches to the flexor carpi ulnaris (FCU): two come from a thick fasciculus at the level of the elbow; one to the proximal portion of the muscle and the other to its middle portion, and the third comes from the distal portion of the same fasciculus to the distal portion of the muscle (Fig. 6).

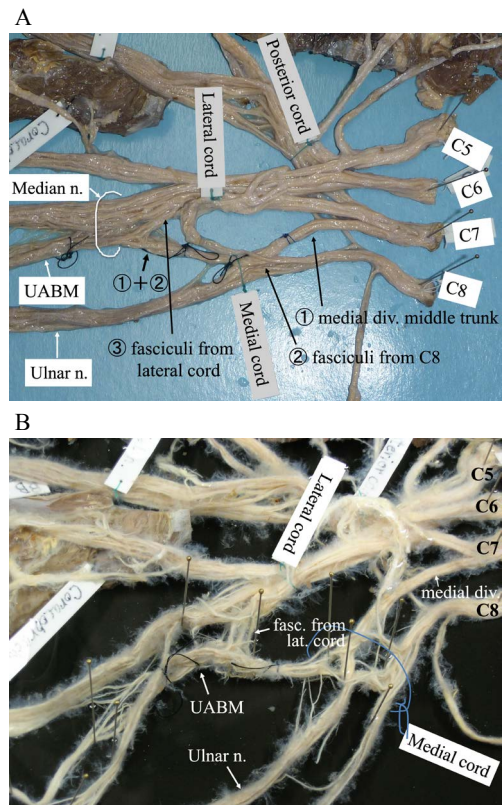


Fig. 4. Components of UABM. A. The UABM is composed of ①fasciculi from the medial division of the middle trunk·C7 root and ②fasciculi from the lower trunk·C8 root, and some from ③the lateral cord. B. Intraneural dissection of the medial cord revealed that one half of fasciculi going to UABM come from the medial division of the middle trunk·C7 root (Eisler) and the other half from the lower trunk·C8 root.

### c) Connecting branches with UABM

In the proximal forearm, a thin branch comes out the radial margin of the ulnar nerve and meets a branch from the ulnar margin of UABM to make a neural arch that gives off motor branches to the flexor digitorum profundus (FDP) of the ring and little fingers (Figs. 6, 7A). A slightly thicker branch comes off the ulnar nerve, a little distal to the third branch to FCU and bifurcates into two nerve branches; a very thin proximal one and a little thicker distal one (Fig. 7B). A thin proximal one unites with the radial bundle (motor fasciculi) of the UABM and

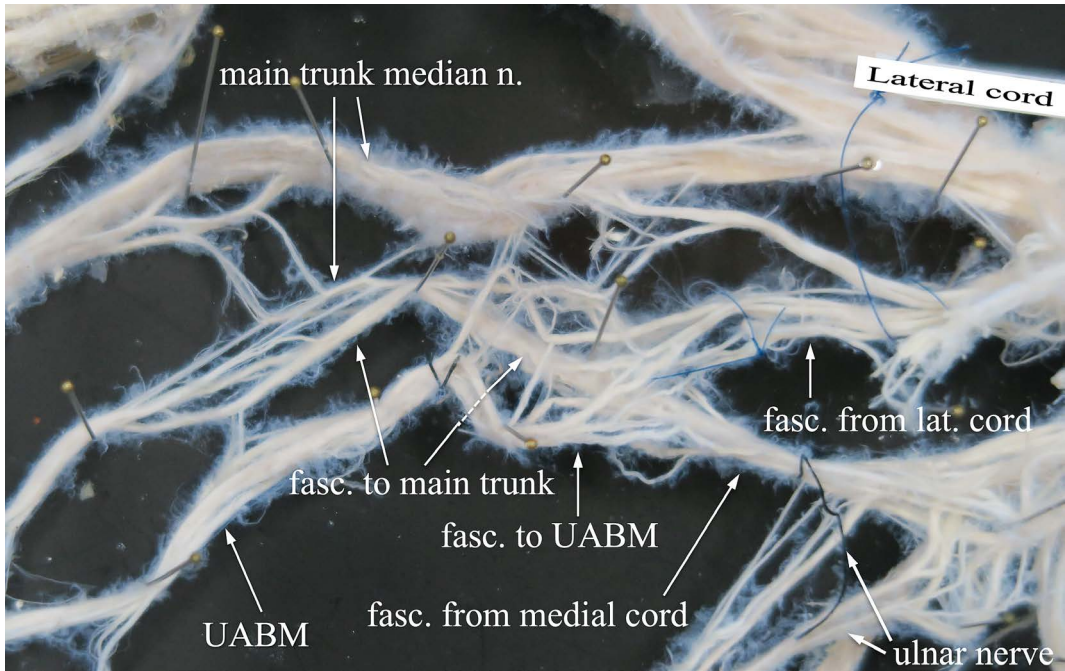


Fig. 5. The route of fasciculi composing the UABM. Several fasciculi of C8 root going to the UABM pass anterior or posterior to the ulnar nerve, two thick fasciculi anterior, and two thick and one thin fasciculi posterior. Three fasciculi from the lateral cord join the UABM.

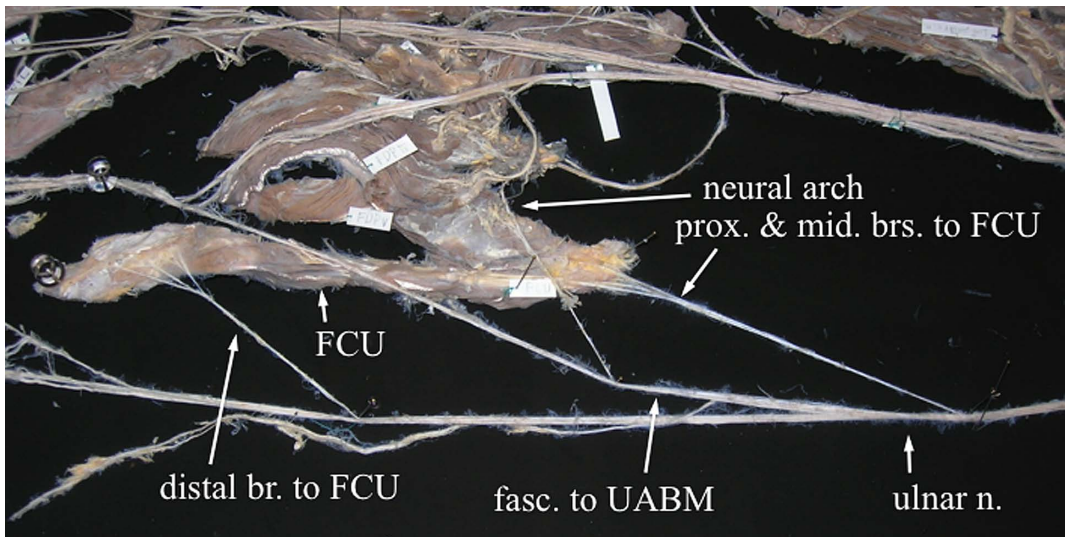


Fig. 6. Motor branches to FCU of the ulnar nerve. Three motor branches to the flexor carpi ulnaris (FCU); two to the proximal and middle portion of the muscle, and another to its distal portion. A thin branch is also seen to meet with a branch from UABM to make a neural arch.

the other thicker distal one unites with its ulnar bundle (sensory fasciculi).

Those findings reveal that the ulnar nerve con-

tains motor fasciculi going to the FDP of the ring and little fingers, FCU and very few motor fasciculi to the intrinsic muscles through a very thin

connection branch going to the radial bundle (motor fasciculi) of the UABM.

#### d) Fasciculi at the level of the wrist

The distal dissection of the remaining bundle of the ulnar nerve showed three fasciculi at the level of the wrist. The first terminates in the fatty tissue at the proximal border of the hypothenar muscles, the second extends along the ulnar border of the hand and the third extends dorsally passing under the tendon of the flexor carpi ulnaris (FCU). All three are thought to be sensory branches.

### Discussion

#### 1) Brachial plexus

The most common type of the human brachial plexus is composed of fasciculi from C5 to Th1 roots. The brachial plexus in this specimen was found to be composed of mainly C5 to C8 roots and the thin nerve root of C4. There was not found any nerve bundle from Th1 or Th2 root. Raven's book "The Anatomy of the Gorilla" (Gregory, 1950) showed a thin nerve bundle of Th1 root to join the lower trunk on the plate 22. So, the brachial plexus of this specimen is considered to be such a type as the prefixed type in humans.

Proximal dissection of the UABM toward the level of the cervical roots revealed that most nerve fibers innervating the ulnar intrinsic muscles of the hand come through the middle trunk·C7 root while most come through the ulnar nerve emerging from the lower trunk composed of C8 and Th1 roots in the common type of the human.

In this specimen, the subclavian artery was found to split the middle trunk into two bundles, upper and lower (Fig. 3B). The upper bundle consists of the anterior and posterior divisions. The lower bundle is the medial division (Eisler) going to the medial cord. This medial division of the middle trunk is not seen in the common type of the human brachial plexus shown in "Correlative Neuroanatomy and Functional Neurology"

(Chusid and McDonald, 1964). Eisler (1890) showed the medial division of the middle trunk going to the medial cord in Figs. 8 and 9 of his book "Das Gefäss- und Periphere Nervensystem des Gorilla" and described it as the lower strong anterior branch of N. cervicalis VII in the text.

Narakas (1977) also illustrated the medial division of the middle trunk in the Figs. 9–19 presented in his chapter of the surgical management of brachial plexus injuries of the human in Daniel and Terzis' "Reconstructive Microsurgery". He describes that the large central fascicle is almost constantly found in the root C7 and that it contains the majority of axons that will form the median nerve. In that figure, the medial cord is drawn as the thick bundle continuing straight from the middle trunk. The thinner anterior division of the lower trunk composed of C8 and Th1 merges into this thick medial cord. Kusakabe *et al.* (1965) reported the similar structure of the medial cord of the brachial plexus in a chimpanzee they dissected. In their case of a chimpanzee, the anterior branch of C7 root becomes the very short medial cord by merging with the anterior branch of the lower trunk C8·Th1 roots and a thin bundle from the lateral cord. This short medial cord soon sends the median nerve. So, the median nerve is composed of mainly the most nerve fibers of the C7 root and some nerve fibers from the lower trunk C8 and Th1 roots and the lateral cord. It is quite different from the common type of the human brachial plexus in which the middle trunk·C7 root does not participate directly in constituting the median nerve, although its small bundle participate in through the lateral cord.

Nishimura *et al.* (1965) and Kusakabe (1976) describe the brachial plexus of the gibbon; that is different from that of the chimpanzee or the human. The anterior branches of the three trunks: upper, middle and lower constitute the fasciculus anterior (the anterior cord) from which the median nerve comes out.

In our case of a gorilla, the nerve fibers emerging from the anterior horn cell of the C7 segment has to get the route going to the intrinsic muscles

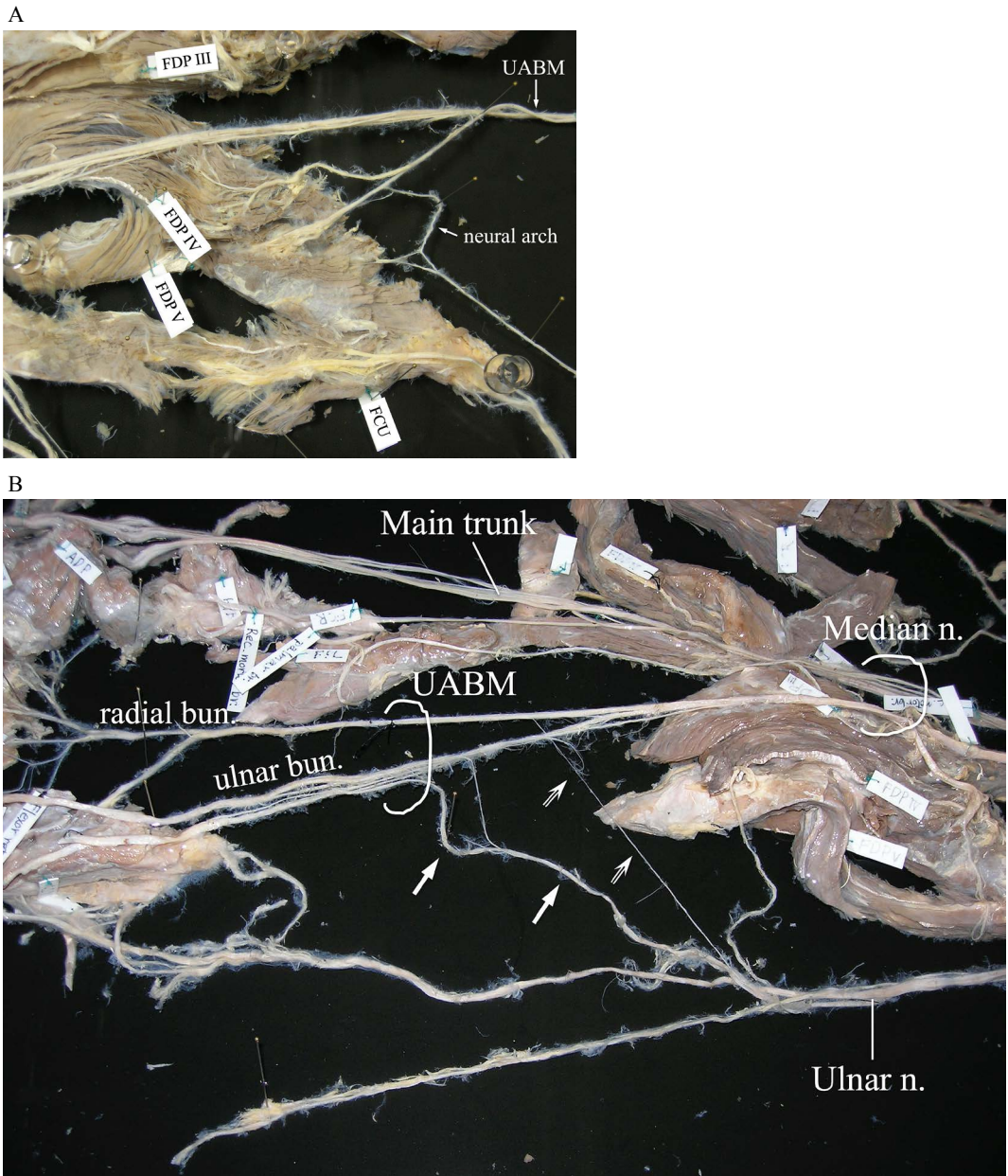


Fig. 7. Connection between UABM and ulnerv nerve. A. In the proximal forearm, a thin branch from the ulnar nerve meets a branch from the UABM to make a neural arch that gives off motor branches to the flexor digitorum profundus (FDP) of the ring and little fingers. B. A thin proximal branch (hollow arrow) from the ulnar nerve unites with the radial bundle (motor fasciculi) of the UABM and the other thicker distal one (solid arrow) unites with its ulnar bundle (sensory fasciculi).

of the hand. The medial division of the middle trunk is considered to be its route going to the medial cord and finally intrinsic muscles. The intraneural dissection of UABM toward the cer-

vical roots revealed that nearly 6/10 of the nerve fibers of the medial root of UABM went to the medial cord and finally to the middle trunk·C7 root. So, the medial division of the middle trunk



was proved to be the route through which those nerve fibers go to the medial cord.

Hollinshead (1969) illustrated the variations in arterial relations to the human brachial plexus but there was not any schema showing the same variation as seen in our specimen in which the subclavian artery split the middle trunk into two bundles.

Regarding the contribution of the middle trunk·C7 root to the medial cord in the human brachial plexus, Hollinshead (1969) quoted Kerr's observation in which the medial cord receives a contribution from the C7 root through a thin branch in a few cases.

## 2) Ulnar antebrachial branch of the median nerve (UABM)

In Raven's book (Gregory 1950), the same nerve bundle as UABM seen in this specimen is drawn on the plate 40 as "Ramus anastomoticus n. medianus cum ulnaris". This branch is also named as "the ramus ulnaris of the nervus medianus" in the text of this book. This ramus is described as follows: it courses distally and receives two anastomosing branches from the ulnar nerve and then it divides into superficial and deep branches eight centimeters above the pisiform. Its deep ramus passes deep to the pisohamate ligament; beneath this ligament it gives off twigs to the m. palmaris brevis, m. abductor digiti quinti, m. flexor digiti quinti brevis and m. opponens digiti quinti. The remainder of the nerve then swings laterally distal to the os hamatum, giving twigs to the third and fourth lumbricales, the mm. interossei and the m. adductor pollicis; caput transversum and caput obliquum.

On the other hand, the ulnar nerve is described in this book as follows. "As the ulnar nerve passes behind the medial epicondyle it gives off branches to the proximal part of FCU, and a small branch to the elbow joint, next, a branch to FDP that joins a branch from the median nerve before it enters the muscle, and then a large branch to FCU after it has sent two branches to the ramus ulnaris of the median nerve." This route of the ulnar nerve is nearly identical to that

observed in our specimen (Figs. 6, 7A, 7B).

On the plate 40, the ramus anastomoticus n. medianus cum ulnaris (UABMN), after receiving the connecting branch from the ulnar nerve in the mid-forearm, is indicated as "Ramus profundus n. ulnaris" with a leading line shown at the level of the wrist. Although this note indicated with a leading line causes a misunderstanding that UABM unites with the main trunk of the ulnar nerve, it does not. The main trunk of the ulnar nerve is recognized on the plate 40. According to the description in the text, it passes dorsally after sending two communicating branches to UABM and perforates the deep fascia between FCU and the ulna 4 cm above the pisiform. It terminates as the cutaneous nerve of the medial side of the dorsum of the hand.

Eisler (1890) described the course of the median nerve in detail in "Gefäss- und periphere Nervensystem des Gorilla" but did not refer to such a branch as UABM. Preuschhof (1964) did not refer to such a branch of the median nerve either in "Die Nerven der Vorderextremität des Gorilla". Hepburn (1892) described the innervations of muscles in the forearm and cutaneous nerve supply of the hand in the gorilla but did not mention such a branch as UABM at all. So, UABM seems to be either the variation or anomaly in the nervous system of the forelimb of the gorilla.

Such a branch of the median nerve as UABM seen in our specimen of gorilla is not described in any established textbooks of the human anatomy mentioned above, even in Tountas and Bergman's book (1993) "Anatomic Variations of the Upper Extremity".

Okubo *et al.* (1977) showed seven types (1st~3rd main types with two subtypes each and 4th type) in photographs. Each connection branch emerging from the anterior interosseous nerve or the main trunk of the median nerve is pretty thick and not very short. Those branches, however, join to the main trunk or muscular branches of the ulnar nerve.

The UABM seen in our specimen takes its own route to the hand to innervate ulnar intrinsic muscles and sensibility of the ulnar 1/3 of the

hand although it receives two connection branches coming from the main trunk of the ulnar nerve.

The connection between the median and the ulnar nerves seen in the human forearm is called Martin-Gruber anastomosis. Martin first described this connection in 1763 and then Gruber reported in 1870 that it was found in 38 (17.9%) of 212 limbs (Leibovic and Hastings, 1992). Okubo *et al.* (1977) quoted the incidence reported being 10 to 44%.

It has been known that there are occasionally seen cases in which the ulnar intrinsic muscles are not paralyzed when the ulnar nerve is cut or anesthetized at the elbow or the proximal forearm (Kaplan, 1965; Mannerfelt, 1966; Okubo *et al.*, 1977). The explanation for this paradoxical phenomenon is that the motor fibers innervating those intrinsic muscles come through the median nerve in the arm and then the Martin-Gruber anastomosis in the forearm.

In our gorilla, there are two connecting branches between UABM and the ulnar nerve in the proximal forearm. A very thin proximal branch unites with the radial bundle (motor fasciculi) of UABM and the other thicker distal one unites with its ulnar bundle (sensory fasciculi). The very thin proximal branch coming from the ulnar nerve might take a part in innervating ulnar intrinsic muscles.

It is a critical anatomical variation put into the mind on making a clinical diagnosis and treating nerve injuries in the upper arm and around the elbow. Leibovic and Hasting (1992) classified Martin-Gruber anastomosis into 6 types according to not only the pattern of communication seen by the naked eye but also which nerve fibers, the median nerve or the ulnar nerve, innervate the intrinsic muscles by using an EMG technique.

The UABM seen in this specimen first goes toward the ulnar side of the wrist and it bifurcates into two bundles in the distal forearm. Its radial bundle innervates all ulnar intrinsic muscles and so it resembles the type II of Leibovic's classification. It is not identical to that type

because it goes through the own branch of the median nerve, not through that of the ulnar nerve.

When such a branch coming out the median nerve and innervating ulnar intrinsic muscles as Leibovic's type Ib or II exists in the human, all intrinsic muscles (both radial and ulnar intrinsic muscles) of the hand shall be innervated by nerve fibers coming through the median nerve. Such a type of innervation is called as "all median hand" proposed by Marinacci and von Hagen (1965). So, laceration of the ulnar nerve at the medial aspect of the elbow or the proximal forearm, entrapment of the ulnar nerve with osteoarthritis of the elbow joint will not elicit functional disturbance due to intrinsic paralysis of the hand.

Hepburn (1892) stated, in his thesis on his own anatomical dissection of four species of anthropoids; Gorilla, Chimpanzee, Orangutan and Gibbon, one head each, "In the Gorilla, Chimpanzee and Gibbon, distinct branches of communication existed between the median and ulnar nerves in the forearm." This statement suggests that the connection between the median and the ulnar nerves is the invariable phenomenon in anthropoids.

### 3) Causative factors of UABM

The variation in the cervicobrachial region is important as far as the development of UABM is concerned. Which cervical segment those nerve fibers innervating the ulnar intrinsic come out, and which trunks or cords those come through; those two factors seem to be crucial. Which compartment of the upper arm those nerve fibers come down depends on those. The median nerve comes down in the anterior compartment of the upper arm while the ulnar nerve in the posterior one. Those two compartments are separated by the thick fascia; the medial brachial intermuscular septum. Fasciculi composing UABM have extended anteriorly along the median nerve over the proximal margin of this septum at the early stage of embryonic development. In this specimen, the subclavian artery splits the division branch of the middle trunk into two and also there was such a variation as high division of the

brachial artery which bifurcates into the radial and the ulnar arteries at the level a little proximal to the midlevel of the biceps brachii. These vascular variations might have some relation to embryonic development of this variation of the median nerve.

Another hypothetical cause is an accidental change of the route during the embryonic development. If the neurons, the first and the second, are destined to innervate the targeting muscles from the beginning of the development, it is understandable that the route of the fascicular bundle took another route by accident while nerve fibers were being bundled. However, there are two papers regarding the muscle and innervating nerve during the embryonic development that are against this hypothesis. Akita (1997) quoted the Stranznicky's (1963) experimental result of the chicken and referred to the conclusive idea of Hollyday and Hamburger (1977) that the muscle and its innervating nerve is not destined.

Kusakabe (1976) describes in his paper entitled "The structure of brachial plexus in anthropoids" that there is the myotome in the limb which is the primitive form of the muscle and that the nervous tissue develops in each muscle segment at the early stage of embryonic development. It repeats union and division to grow distally to be the nerve plexus unique to each species of the animal while a myotome gradually develops into the muscular tissue.

In this specimen, the mechanism of development of UABM is surmised as follows; the nervous tissue from the anterior horn cells of the C7, one segment cranial than the common type in the human anatomy, reaches the myotome of intrinsic muscles of the hand earlier than that of the C8, Th1 one or two segments below, and grows distally with the extending nerve fibers. Those nerve fibers were bundled with the median nerve rather than the ulnar nerve during the embryonic development.

#### 4) Significance

The significance of this anatomical course of

those motor fibers through the median nerve is not clear. The route of this nerve bundle (UABM) is advantageous to avoid the dysfunction of the hand caused by ulnar nerve palsy after injuries at the medial aspect of the elbow, or with osteoarthritis of the elbow joint, to both of which gorillas are very susceptible during their wild lives. On the other hand, the median nerve injury in the upper arm or at the elbow could cause paralysis of all (both ulnar and radial) intrinsic muscles of the hand.

#### Acknowledgements

The author is very grateful to Shinichiro Kawada who supported him for providing and preserving the specimen at the Department of Zoology, National Museum of Nature and Science in Tsukuba, Japan.

#### References

- Anderson, J. E. 1983. *Grant's Atlas of Anatomy*. 8th ed. Williams & Wilkins, Baltimore., Section 6 (The upper limb), Section 9 (The neck), (no pagination in this book).
- Akita, K. 1997. How is the muscle formed (in the fetus)? *Journal of Society of Biomechanisms Japan* 21(4): 152–156 (in Japanese).
- Boileau Grant, J. C. and J. V. Basmajian 1965. *Grant's Method of Anatomy*. 7th ed. Williams & Wilkins, Baltimore. pp. 125–158, 552–558.
- Chusid, J. G. and J. J. McDonald 1964. *Correlative Neuroanatomy and Functional Neurology*. 9th ed. Lange Medical Publications, Los Altos, CA. pp. 101–112.
- Eisler, P. 1890. *Das Gefäß- und Periphere Nervensystem des Gorilla*. Tausch & Grosse, Halle a. S., pp. 39–50, Taf. IV.
- Gregory, W. K (Ed) 1950. *The Anatomy of the Gorilla: The Henry Cushier Raven memorial volume*. Columbia University Press, New York. pp. 32–48, p. 116 (Plate 22), p. 134 (Plate 40).
- Hepburn, D. 1892. The comparative anatomy of the muscles and nerves of the superior and inferior extremities of the anthropoid apes. *Journal of Anatomy and Physiology* 26: 149–186.
- Hollinshead, W. H. 1969. *Anatomy for Surgeons Vol. 3 The Back and Limbs*. 2nd ed. Harper & Row Publishers, New York. pp. 207–210, 225–259, 349–441, 446–569.

- Hollyday, M. and V. Hamburger 1977. An autoradiographic study of the formation of the lateral motor column in the chick embryo. *Brain Research* 132: 197–208.
- Kaplan, E. B. 1965. *Functional and Surgical Anatomy of the Hand*. 2nd ed. JB Lippincott, Philadelphia. pp. 153–168.
- Kusakabe, A., H. Shiozumi, S. Ounaka and H. Mizoguti 1965. Plexus brachialis of a Chimpanzee (*Pan satyrus* L.). *Kaibougaku-Zasshi* 40: 183–191 (in Japanese).
- Kusakabe, A. 1976. The structure of brachial plexus in anthropoids. *The Otani-Gakuho* 56(3): 1–19 (in Japanese).
- Lampe, E. W. and F. H. Netter 1951. *Surgical Anatomy of the Hand; with special reference to infection and trauma*. Ciba Clinical Symposia Vol. 3. No. 8. Ciba Pharmaceutical Products, Inc., Summit, NJ. pp. 263–305.
- Lampe, E.W. 1976. *Surgical anatomy of the hand*. Clinical Symposia Anthology: Musculoskeletal System. Ciba-Geigy Japan, Takarazuka. pp. 55–86 (in Japanese; translated into Japanese by Iwata H. *et al.*).
- Leibovic, S. J. and H. Hasting II 1992. Martin-Gruber revisited. *Journal of Hand Surgery* 17A: 47–53.
- Mannerfelt, L. 1966. Studies on the hand in ulnar nerve paralysis; A clinical-experimental investigation in normal and anomalous innervation. *Acta Orthopaedica Scandinavica Supplementum* No. 87. pp. 21–26, 130–142.
- Marinacci, A. A. and K. O. von Hagen 1965. Misleading “all median hand”. *Archives of Neurology* 12: 80–83.
- Narakas, A. 1977. The surgical management of brachial plexus injuries. In Daniel R. K. and J. K. Terzis (eds.): *Reconstructive Microsurgery*, pp. 443–460. Figs. 9–19. Little Brown Co., Boston.
- Nishimura R., A. Kusakabe, S. Ounaka and H. Mizoguti 1965. Plexus brachialis of a Gibbon (*Hylobates agilis* [F. Cuvier, 1821]). *Kaibougaku-Zasshi* 40: 235–245 (in Japanese).
- Okubo K., Y. Itami, K. Murota, S. Morita and T. Kato 1977. Studies on an anastomosis between the median and ulnar nerve (Martin-Gruber anastomosis) in the forearm. *Saigai-Igaku* 20: 903–912 (in Japanese).
- Preuschoft, H. 1964. Die Nerven der Vorderextremität des Gorilla (Gorilla gorilla Savage et Wyman, 1847). *Anatomischer Anzeiger* 115: 313–334.
- Saito, H. 2020. The nerve bundle via the median nerve innervating the intrinsic muscles in a gorilla. *ASSH Perspectives*, January 2020 edition, American Society for Surgery of the Hand. <http://asshperspectives.org/2020/01/the-nerve-bundle-via-the-median-nerve-innervating-the-intrinsic-muscles-of-the-hand-in-a-gorilla/> [Accessed on April 13, 2023].
- Saito, H., T. K. Yamada and Y. Tajima 2021. Anatomical study of the right forearm and hand of one gorilla for comparison with humans with respect to motion of the thumb and fingers. *Bulletin of the National Museum of Nature and Science. Series A* 47: 135–155.
- Straznický, K. 1963. Function of heterotopic spinal cord segments investigated in the chick. *Acta Biologica Hungarica* 14: 143–153.
- Tountas, C. P. and R. A. Bergman. 1993. *Anatomic Variations of the Upper Extremity*. Churchill Livingstone, New York. pp. 211–240.
- Ueba Y. 1985. *Hand: Its Function and Anatomy*. 2nd ed. Kinpodo, Kyoto. pp. 179–217 (in Japanese).